Check for updates

Review Article

Current Multidisciplinary Management of Brain Metastases

Michael J. Moravan, MD, PhD [1,2]; Peter E. Fecci, MD, PhD[3]; Carey K. Anders, MD[4]; Jeffrey M. Clarke, MD[4]; April K. S. Salama, MD[4]; Justus D. Adamson, PhD[1]; Scott R. Floyd, MD, PhD [1]; Jordan A. Torok, MD[1]; Joseph K. Salama, MD[1,2]; John H. Sampson, MD, PhD, MBA, MHSc[1,3]; Paul W. Sperduto, MD, MPP[5,6]; and John P. Kirkpatrick, MD, PhD[1,3]

Brain metastasis (BM), the most common adult brain tumor, develops in 20% to 40% of patients with late-stage cancer and traditionally are associated with a poor prognosis. The management of patients with BM has become increasingly complex because of new and emerging systemic therapies and advancements in radiation oncology and neurosurgery. Current therapies include stereotactic radiosurgery, whole-brain radiation therapy, surgical resection, laser-interstitial thermal therapy, systemic cytotoxic chemotherapy, targeted agents, and immune-checkpoint inhibitors. Determining the optimal treatment for a specific patient has become increasingly individualized, emphasizing the need for multidisciplinary discussions of patients with BM. Recognizing and addressing the sequelae of BMs and their treatment while maintaining quality of life and neurocognition is especially important because survival for patients with BMs has improved. The authors present current and emerging treatment options for patients with BM and suggest approaches for managing sequelae and disease recurrence. ***Cancer* 2020;126:1390-1406**. *© 2020 American Cancer Society*.

KEYWORDS: brain metastases, immunotherapy, laser-interstitial thermal therapy, radiation therapy, radionecrosis, stereotactic radiosurgery.

INTRODUCTION

Brain metastases (BMs) are the most common adult intracranial malignancy, affecting 200,000 to 300,000 new patients per year in the United States and representing 20% to 40% of patients with advanced-stage cancer.[1] Lung, breast, melanoma, renal cell, and colorectal cancers represent the majority of BMs.[2] BM incidence is increasing because of the higher resolution and greater frequency of brain imaging and more effective control of extracranial disease as a result of improvements in systemic therapy.

Although BMs are common, the clinical presentation varies, depending on size, number, and location. Headache is the most commonly reported symptom and typically is associated with multiple and/or posterior fossa BMs. Patients may also present with focal neurologic dysfunction, seizures, stroke-like symptoms, and/or subtle cognitive dysfunction. Clinicians should have a high suspicion for BM in patients who have advanced cancer with neurologic complaints.

BM detection in patients with cancer is important for accurate staging and optimal management. Symptomatic patients commonly receive a noncontrast-enhanced computed tomography (CT) scan of the head to rule out life-threatening conditions, which may suggest a diagnosis of BM, but it is not sensitive enough for staging. Thin-cut (≤1.5 mm), brain magnetic resonance (MR) imaging (MRI) with and without intravenous gadolinium contrast is preferred for BM screening and has increased sensitivity compared with contrast-enhanced CT scans.[3-5] For patients with contraindications to MRI, contrast-enhanced CT scans may be used. On cross-sectional, contrast-enhanced imaging, BMs are typically spherical, ring-enhancing lesions with surrounding vasogenic edema, commonly located at the gray-white matter junction. On MRI, they usually appear isointense or hypointense on T1-weighted images and hyperintense on T2-weighted images; however, some can be hyperintense on T1 imaging (depending on histology or the presence of hemorrhage). Vasogenic edema is hypointense on T1-weighted imaging and hyperintense on T2-weighted imaging but is best evaluated on fluid-attenuated inversion recovery imaging, which suppresses the T2 hyperintensity associated with cerebrospinal fluid (CSF) in the ventricles and surrounding the brain. BMs are usually hyperintense on fluid-attenuated inversion recovery imaging.[6] These MRI characteristics, however, are not pathognomonic for BMs, and the differential diagnosis includes primary brain tumors, infection, demyelinating disease, and vascular abnormalities. Additional MRI sequences and other imaging modalities can be helpful in identifying

Corresponding Author: Michael J. Moravan, MD, PhD, Department of Radiation Oncology, Duke University Medical Center, Box 3085, Durham, NC 27710 (michael.moravan@duke.edu).

[1]Department of Radiation Oncology, Duke University Medical Center, Durham, North Carolina; [2]Department of Radiation Oncology, Durham Veterans Affairs Medical Center, Durham, North Carolina; [3]Department of Neurosurgery, Duke University Hospital, Durham, North Carolina; [4]Department of Internal Medicine, Division of Medical Oncology, Duke University Hospital, Durham, North Carolina; [5]Minneapolis Radiation Oncology, Minneapolis, Minnesota; [6]University of Minnesota Gamma Knife Center, Minneapolis, Minnesota

DOI: 10.1002/cncr.32714, **Received:** September 25, 2019; **Revised:** December 8, 2019; **Accepted:** December 19, 2019, **Published online** January 23, 2020 in Wiley Online Library (wileyonlinelibrary.com)

and evaluating BMs to better differentiate them from other pathologies, such as diffusion-weighted MRI, diffusion-tensor MRI, MR spectroscopy, MR perfusion, and positron emission tomography (PET).[7-9]

PROGNOSTIC ASSESSMENT

Historically, untreated patients with BMs experienced a 1-month to 2-month median overall survival (OS),[10] and whole-brain radiation therapy (WBRT) extended this to approximately 4 to 6 months.[11] With modern systemic therapies, supportive care, and early hospice/palliative interventions, post-WBRT survival is slightly better (7-8 months).[12] Several prognostic indices exist for patients with BMs,[13] which evolved from a recursive partitioning analysis that divided patients into 3 prognostic classes based on performance status (PS), extent/control of extracranial disease, and age to the graded prognostic analysis (GPA) by adding the number of BMs. Next, diagnosis-specific GPAs for lung, melanoma, renal cell, breast, and gastrointestinal cancers were created; and, finally, molecular markers were added to develop molecular GPAs for non–small-cell lung cancer (NSCLC) and melanoma.[14,15] Although the clinical value of these tools has been limited and overall performance status tends to drive clinical management, they serve to better educate the patient and enable a more informed understanding of the potential risks and benefits of the various treatment modalities.

SYMPTOM MANAGEMENT

Because BMs can significantly affect quality of life (QoL), symptom management is a key component of appropriate clinical care. Early palliative care intervention improves OS and QoL and especially benefits patients with significant symptom burden.[16] Typically, symptomatic BMs are managed adequately with corticosteroids (commonly dexamethasone) by reducing peritumoral edema and intracranial pressure. A common dexamethasone regimen is a 10-mg loading dose followed by 4 to 6 mg every 6 hours, although lower doses (4-8 mg daily) can achieve symptom control.[17] Using the lowest effective dose minimizes steroid-related toxicity but also may result in less suppression of immunotherapy effects. Conflicting data exist regarding whether all patients who receive ≥10 mg prednisone daily (or equivalent) at the initiation of single-agent, programmed cell death-1 (PD-1) or programmed death ligand 1 (PD-L1) inhibitors have worse OS and progression-free survival (PFS) compared with patients who require <10 mg.[18-20] Further investigation is necessary to determine the effects of corticosteroid use and their timing on the efficacy of immune checkpoint inhibition (ICI) therapy either alone or in conjunction with chemotherapy. Importantly, some patients who required corticosteroids in the aforementioned studies did demonstrate a response to ICI, so patients should not be excluded from immunotherapy if they are receiving corticosteroids. Finally, steroids are not recommended for patients with asymptomatic BMs.

For patients who present with seizures, single-agent, standard, first-line antiepileptics should be used at the lowest effective dose to minimize medication toxicity. Antiseizure medication use for prophylaxis in patients without a seizure history is not recommended and is associated with more adverse effects.[21,22] Typically, patients undergoing BM resection are placed on a prophylactic antiseizure medication in the postoperative period because seizures in this setting can be devastating, although published evidence supporting this practice is limited.[23]

THE ROLE OF SURGERY

Many patients can benefit from surgical resection, given improvements in neuroanesthesia, neuroimaging, and operative instruments. Resection can provide rapid symptom relief secondary to mass effect and/or CSF obstruction, provides tissue for histopathology, and is appropriate for large, symptomatic (>3 cm) tumors. For patients with a single BM, most studies demonstrate improved survival for patients who receive WBRT and surgery versus WBRT alone.[24]

For patients with multiple BMs, the role of resection is less clear and typically, multiple BMs are a relative contraindication for resection. Because of the increased technical difficulty in accessing and resecting multiple BMs, patient selection is paramount. Retrospective data suggest a possible benefit in patients with limited BMs, those with multiple BMs that cause symptomatic mass effect or CSF obstruction, and/or when multiple BMs are accessible from the same craniotomy.[25-27] One study compared patients with limited BMs (n = 2-3) versus those with a single BM, all of whom underwent complete resection followed by WBRT and found that the median OS was not different between the groups (14 months).[27] Of note, recurrence rates, complication rates per craniotomy, and 30-day mortality rates were similar between the 2 groups. In our practice, multiple BM resections are limited to patients who have a good

10970142, 2020, 7, Downloaded from https://acsjournals.onlinelibrary.wiley.com/doi/10.1002/cncr.32714, Wiley Online Library on [03/02/2026]. See the Terms and Conditions (https://onlinelibrary.wiley.com/terms-and-conditions) on Wiley Online Library for rules of use; OA articles are governed by the applicable Creative Commons License

PS with 2 large (>3 cm), surgically accessible, symptomatic lesions.

For recurrent BMs, resection can improve survival and PS status,[28] especially for patients who have controlled extracranial disease, a preoperative Karnofsky PS >70, a time-to-recurrence ≥4 months, age <40 years, and nonbreast/melanoma histology. Surgical resection of recurrent BMs can be considered in patients who have a good PS with limited intracranial disease and controlled extracranial disease.

THE ROLE OF POSTOPERATIVE RT

After resection, patients with BMs have an approximately 60% 12-month tumor bed recurrence rate.[29] Adjuvant WBRT reduces central nervous system (CNS) recurrence rates and the risk of neurologic death.[24] Stereotactic radiosurgery (SRS) is another option to precisely deliver targeted high-dose radiation to the resection cavity, minimizing dose to the surrounding normal brain tissue, and potentially resulting in less adverse neurocognitive effects than WBRT. A single-center, randomized phase 3 study was conducted to compare postoperative single-fraction SRS (SF-SRS) with observation alone after BM resection.[29] With a primary endpoint of local recurrence, it was noted that postoperative SRS significantly reduced tumor bed recurrence (12-month freedom from local recurrence, 72% with postoperative SRS vs 43% with observation; hazard ratio, 0.46; $P = .015$). No serious adverse events (AEs) were noted in the SRS group; and, although the analysis was not powered for survival, no difference was noted between groups, and most patients who had local recurrences received salvage treatment with SRS, WBRT, surgery, or a combination thereof. An important observation was the high rate of new BMs, which occurred in approximately 60% of patients in both treatment groups over 1 year. Another key prospective, randomized study compared the use of postoperative SRS versus WBRT using coprimary endpoints of cognitive-deterioration–free survival and OS. SRS was associated with superior cognitive-deterioration–free survival (median, 3.7 months vs 3 months; hazard ratio, 0.47; $P < .0001$), and cognitive deterioration at 6 months was less frequent in those who underwent SRS versus those who received WBRT (52% vs 85%, respectively).[30] The median survival was similar in both groups at approximately 12 months. However, WBRT resulted in prolonged intracranial tumor control, with a higher rate of surgical bed control at 12 months (80% vs 60%). Despite the potential inferior local control, the authors concluded that SRS should be considered a standard of care considering the reduction in neurotoxicity and similar OS. Several possible explanations for the reduced local control with SF-SRS include reduced and potentially inadequate, single-fraction doses for large surgical beds; a hypoxic environment after surgery; and challenges with target volume design after surgery. One alternative approach would be hypofractionated SRS (HF-SRS), with the dose being delivered over 3 to 5 sessions, which would allow for a higher total dose and, theoretically, without increasing toxicity. The Alliance cooperative group recently activated a randomized phase 3 trial (clinicaltrials.gov identifier NCT04114981) comparing SF-SRS versus fractionated SRS (3-5 sessions) for patients with resected BMs using a primary endpoint of surgical bed recurrence-free survival. In addition, patterns of recurrence after SRS may better inform target volume delineation, in which larger margins may be necessary especially when dural contact is present.[31] Another alternative approach to mitigate recurrence would be to offer preoperative SRS. In 1 of the larger single-institution experiences, the 1-year tumor bed recurrence rate after preoperative SRS was approximately 20%.[32] How this compares with postoperative SRS is the subject of another randomized phase 3 trial (clinicaltrials.gov identifier NCT03741673), in which the rates of leptomeningeal disease, local control, distant BM, and OS will be compared between preoperative versus postoperative. After BM resection and tumor bed SRS regular brain MRIs are required considering the risk for both local and distant brain recurrence because multiple salvage options are feasible should intracranial disease progression be observed.

SYSTEMIC TREATMENT OF BRAIN METASTASES

Extracranial disease can pose a greater threat than BMs in patients who have small (≤2 cm) and/or asymptomatic BMs, emphasizing the need for timely systemic therapy. Historically, upfront chemotherapy was not used in patients with BM given concern for poor CNS penetration.[33] Recently, targeted therapies and ICI have resulted in improved extracranial and intracranial disease control in specific cancer histologies and have led to increasingly individualized treatment, further emphasizing the need for multidisciplinary care.[8]

Melanoma

Melanoma represents approximately 11% of all patients with BMs. Although chemotherapy yields poor overall

10970142, 2020, 7, Downloaded from https://acsjournals.onlinelibrary.wiley.com/doi/10.1002/cncr.32714, Wiley Online Library on [03/02/2026]. See the Terms and Conditions (https://onlinelibrary.wiley.com/terms-and-conditions) on Wiley Online Library for rules of use; OA articles are governed by the applicable Creative Commons License

response rates (ORRs), BRAF and MEK inhibitor (BRAF/MEKi) therapy and ICI have demonstrated improved extracranial and intracranial ORRs.[8] The COMBI-MB trial (Dabrafenib Plus Trametinib in Patients With BRAF^{V600}-Mutant Melanoma Brain Metastases) demonstrated the utility of BRAF/MEKi therapy, in which patients who had BRAF^{V600}-mutant melanoma with asymptomatic and symptomatic BMs and received BRAF/MEKi therapy had intracranial response rates of ≥44%.[34] Interestingly, the patients who had melanoma with symptomatic BMs had an intracranial response rate of 59%. The median duration of response ranged from 4.5 to 8.3 months, depending on the cohort, emphasizing the need for regular MRI surveillance in these patients. Taken together, BRAF/MEKi therapy, close MRI surveillance, and deferral of BM-directed therapy until CNS disease progression can be considered on a case-by-case basis in patients with BRAF^{V600}-mutant melanoma and BMs who meet the inclusion criteria for the COMBI-MB trial, after multidisciplinary evaluation. It is the authors' approach to consider upfront, BM-directed therapy for patients who do not meet inclusion criteria of the COMBI-MB trials, especially in cases where BM progression would carry significant morbidity.

ICI therapy has revolutionized the treatment landscape for patients with advanced melanoma, including those with BMs. Intracranial response rates in patients who have melanoma with asymptomatic BMs and receive either single-agent ipilimumab or anti–PD-1 therapy range from 16% to 26%.[8] Nivolumab with ipilimumab increases extracranial and intracranial disease control compared with either treatment alone, although combination therapy increases the risk of AEs.[35,36] CheckMate204 (An Investigational Immuno-Therapy Study to Evaluate Safety and Effectiveness in Patients With Melanoma That Has Spread to the Brain, Treated With Nivolumab in Combination With Ipilimumab, Followed by Nivolumab by Itself; clinicaltrials.gov identifier NCT02320058) demonstrated an intracranial response rate of 55%, a 12-month intracranial PFS rate of 59.5%, and an intracranial clinical benefit rate of 58.4% for patients who had asymptomatic melanoma with BMs and received nivolumab/ipilimumab; however, approximately 55% of patients experienced grade ≥3 AEs, including 1 death.[36,37] Patients who had immunotherapy-naive, non–CNS-treated melanoma with asymptomatic BMs had higher 12-week intracranial response rates after receiving nivolumab/ipilimumab compared with nivolumab alone (46% vs 20%, respectively). Of note, intracranial response rates were lower in patients who were previously treated with BRAF/MEKi and in those who had progression of previously treated BMs, neurologic symptoms, and/or leptomeningeal disease treated with nivolumab alone.[35] CheckMate204 reported similarly poor outcomes for patients who had melanoma with symptomatic BMs and received combination ipilimumab/nivolumab, with an intracranial response rate of 16.7% and a clinical benefit rate of 22.2% after a median follow-up of 5.3 months. ICI therapy with close MRI surveillance and deferral of BM-directed therapy until CNS disease progression is an option for patients who have melanoma with small (≤2 cm), asymptomatic BMs, although multidisciplinary input is critical. Patients who have melanoma with symptomatic BMs, larger BMs (>2 cm), those who have intracranial disease progression on ICI or BRAF/MEKi therapy, or those in whom BM progression would carry significant morbidity should proceed with BM-directed therapy before they initiate or change systemic therapies because of the lower intracranial response rates to ICI reported in these settings.

Non–Small-Cell Lung Cancer

Lung cancer accounts for up to 50% of patients with BMs. Approximately 10% of patients who have advanced-stage NSCLC present with BMs, and approximately 20% develop BMs during their disease course, although particular genetic mutations can increase the incidence of BM.

Anaplastic Lymphoma Kinase and ROS1 Translocations

The *EML4*-anaplastic lymphoma kinase (*ALK*) fusion oncogene is present in approximately 5% of patients with NSCLC and in approximately 40% of those who present with BMs. Crizotinib is a tyrosine kinase inhibitor (TKi) that produces improved extracranial ORRs compared with chemotherapy in this setting. Many patients, however, develop resistance and demonstrate disease progression the brain because CNS penetrance is poor. Next-generation TKis appear to be more potent and selective. First-line alectinib and brigatinib provide better PFS, less toxicity, and improved intracranial and extracranial response rates and duration compared with crizotinib.[38] Therefore, patients who have treatment-naive, asymptomatic, *ALK*-positive NSCLC with BMs should be considered for treatment with next-generation TKis, close surveillance, and deferment of BM-directed therapy until CNS disease progression.

Next-generation TKis also demonstrate intracranial activity in patients who have *ALK*-positive NSCLC with CNS disease progression after crizotinib

10970142, 2020, 7, Downloaded from https://acsjournals.onlinelibrary.wiley.com/doi/10.1002/cncr.32714, Wiley Online Library on [03/02/2026]. See the Terms and Conditions (https://onlinelibrary.wiley.com/terms-and-conditions) on Wiley Online Library for rules of use; OA articles are governed by the applicable Creative Commons License

or chemotherapy.[38] For patients who have *ALK*-positive NSCLC with disease progression after crizotinib and platinum-based chemotherapy, alectinib yields greater PFS (7.1 vs 1.6 months, respectively) and a greater CNS ORR (54.2% vs 0%, respectively) compared with second-line chemotherapy. Alectinib has demonstrated CNS activity in patients previously treated with crizotinib and ceritinib who experience progressive leptomeningeal disease. Ceritinib and lorlatinib has demonstrated intracranial response rates of 45% to 50% for crizotinib-resistant or chemotherapy-resistant BMs. Therefore, patients who have asymptomatic, *ALK*-positive, NSCLC with BMs progressing on crizotinib or chemotherapy should be strongly considered for upfront next-generation TKis, close surveillance, and deferred BM-directed therapy until CNS disease progression.

A *ROS1*-receptor tyrosine kinase gene rearrangement occurs in 1% to 2% of patients who have NSCLC, and approximately 36% of these patients present with BMs. First-line therapies include crizotinib and ceritinib, and entrectinib recently gained US Food and Drug Administration approval, although evidence of intracranial activity of these agents in this patient population is limited, and CNS-only disease progression rates on crizotinib are as high as 63%.[39,40] Patients experiencing CNS disease progression on crizotinib should be considered for upfront BM-directed therapy. In the setting of extensive extracranial disease, however, initiating lorlatinib with close surveillance can be considered because there is evidence of intracranial activity in this setting.[39]

Epidermal Growth Factor Receptor Mutations

Historically, patients who had *EGFR*-mutated NSCLC with BMs were treated with upfront BM-directed therapy before first-generation or second-generation TKi therapy, given poor CNS penetrance and worse outcomes with deferral.[41] Currently, osimertinib (a third-generation TKi) is recommended first-line therapy for patients who have asymptomatic, *EGFR*-mutated, NSCLC with BMs, based on improved CNS PFS and an improved CNS ORR (66% vs 43%) with osimertinib treatment compared with first-generation and second-generation TKis.[38] Interestingly, almost all patients who had leptomeningeal disease demonstrated a complete radiographic response.[38] Close brain surveillance is recommended, with BM-directed therapy deferred until CNS disease progression.

For patients who have intracranial and extracranial disease progression on first-generation or second-generation TKis, tumor genotyping (plasma-based or tissue-based) to identify a T790M mutation or other actionable mechanism of resistance is recommended. If they are positive, then neurologically asymptomatic patients should be treated with osimertinib and close surveillance, based on superior PFS, ORR, intracranial ORR, and CNS PFS compared with platinum/pemetrexed therapy.[8] If patients are negative or are experiencing disease progression on osimertinib, then upfront BM-directed therapy is recommended. CNS-only disease progression in these patients is likely because of poor CNS penetration of first-generation/second-generation TKis, so continuing with BM-directed therapy and reserving osimertinib until resistance is acquired is reasonable if osimertinib is unavailable. Alternatively, upfront osimertinib with close surveillance allows for deferral of BM-directed therapy until CNS disease progression and decreases the risk of intracranial progression.

Patients With NSCLC Who Lack Targetable Mutations

Patients who have NSCLC with BMs typically receive upfront BM-directed therapy before cytotoxic chemotherapy. Interestingly, many studies of patients who have synchronous, asymptomatic, NSCLC with BMs and disseminated extracranial disease who receive treatment with platinum-based chemotherapy have reported 30% to 50% overall CNS response rates and randomized trials deferring CNS RT until after chemotherapy or CNS disease progression showed similar median OS.[8,42] Therefore, upfront chemotherapy, close MRI surveillance, and BM-directed therapy deferral until CNS disease progression can be considered for patients who have asymptomatic NSCLC with BM.

Recent data support the integration of ICI therapy into the treatment of patients who have NSCLC with BMs. Two KEYNOTE trials randomized patients with newly diagnosed, metastatic, NSCLC to first-line platinum-based doublet chemotherapy with or without pembrolizumab and found that pembrolizumab improved OS and PFS and had similar toxicity.[43,44] Both trials included patients with untreated BMs (≤1.5 cm in greatest dimension) requiring no steroids and performed short-interval brain MRIs. Subgroup analysis found that patients who had nonsquamous NSCLC with BMs benefited from adding pembrolizumab,[43] but neither study reported the number of patients with active BMs or their specific outcomes. Therefore, upfront chemotherapy and ICI therapy with close surveillance and deferral of BM-directed therapy until

10970142, 2020, 7, Downloaded from https://acsjournals.onlinelibrary.wiley.com/doi/10.1002/cncr.32714, Wiley Online Library on [03/02/2026]. See the Terms and Conditions (https://onlinelibrary.wiley.com/terms-and-conditions) on Wiley Online Library for rules of use; OA articles are governed by the applicable Creative Commons License

CNS disease progression can be considered for patients with asymptomatic NSCLC who meet the KEYNOTE trial inclusion criteria.

Patients who have symptomatic, PD-L1–positive (≥50%) NSCLC with BMs who demonstrate CNS disease progression after first-line systemic therapy should be considered for upfront pembrolizumab with close surveillance, deferring BM-directed therapy until CNS disease progression. A trial of patients who had NSCLC and multiple BMs (78% had received ≥1 previous systemic therapy, and 44% had received no prior CNS therapy) treated with pembrolizumab demonstrated extracranial and intracranial response rates of 33%.[45] Nivolumab and atezolizumab have also demonstrated intracranial activity in patients who had NSCLC with progressing BM; however, most patients had received prior CNS-directed therapies, so deferring BM-directed therapy in this setting is not recommended. Overall data supporting the routine use of ICI therapy in this setting remain limited, and the optimal approach and sequencing of treatment remains unknown.

Breast Cancer

The treatment of patients who have breast cancer with BMs is primarily driven by molecular subtype—hormone receptor-positive/HER2-negative, triple-negative (TNBC), or HER2-positive. Although all breast cancer subtypes can are at risk for BM, the incidence is highest for patients with TNBC (50%) and HER2-positive (30%) disease.[46] For HER2-positive patients who have breast cancer with BMs, lapatinib and neratinib (EGFR/HER2-directed TKis) have intracranial activity as monotherapies (<10%), although intracranial activity increases when these are combined with capecitabine (approximately 30%).[46] More recently, neratinib/capecitabine was compared with lapatinib/capecitabine in patients with advanced, HER2-positive breast cancer showed superior time to intervention for breast cancer BMs in the neratinib arm (overall cumulative incidence, 23% vs 29%; $P = .043$).[47] Tucatinib (an HER2-directed TKi) combined with capecitabine and/or trastuzumab demonstrated ORRs ≥40% in a phase 1b trial for patients with metastatic HER2-positive who had breast cancer with or without BMs and had previously received treatment with trastuzumab, pertuzumab, and trastuzumab emtansine.[48] In patients with previously treated, progressive BMs who were receiving the recommended phase 2 dose of tucatinib, the ORR was 42%. There is currently a phase 3 trial, HER2CLIMB (A Study of Tucatinib vs Placebo in Combination With Capecitabine & Trastuzumab in Patients With Advanced HER2-Positive Breast Cancer; clinicaltrials.gov identifier NCT02614794) evaluating tucatinib versus placebo in combination with capecitabine and trastuzumab. HER2-directed antibodies were hypothesized to be too large to cross the blood-brain barrier; however, case series illustrate durable BM responses to the antibody drug conjugate trastuzumab emtansine.[46] First-line therapy for hormone receptor-positive/HER2-negative breast cancer consists of endocrine therapy with cyclin-dependent kinase 4 and 6 inhibitors (CDK4/6i). Of the currently available CDK4/6i, abemaciclib has the greatest blood-brain barrier permeability. Single-agent intracranial response rates are 6%, with intracranial clinical benefit rates of 25%.[46] Although chemotherapy remains the mainstay for TNBC, several novel agents have shown promise, including a pegylated etirinotecan (NKTR-102). In a randomized, phase 2 study of NTKR-102 versus physician's choice of therapy, patients with stable BMs demonstrated a PFS that was 5.2 months longer, favoring NKTR-102.[49] Although ICI therapy has been approved as first-line treatment for PD-L1–positive TNBC with nab-paclitaxel, intracranial response rates to ICI therapy are largely unknown.[50] Therefore, only select patients who have breast cancer with BMs should be considered for upfront systemic therapy with close surveillance, deferring BM-directed therapy until intracranial disease progression.

Renal Cell Carcinoma

Recently, clinicians have investigated upfront systemic therapy in the treatment of patients who have RCC with active BMs. The GETUG-AFU 26 NIVOREN trial (Nivolumab in Patients With Metastatic Renal Cell Carcinoma Who Have Progressed During or After Prior Systemic Anti-Angiogenic Regimen [NIVOREN]; clinicaltrials.gov identifier NCT03013335) investigated nivolumab use in patients who had clear cell RCC with asymptomatic BMs (≥5 mm) and experienced CNS disease progression on vascular endothelial growth factor-directed therapies.[51] One patient cohort received focal treatment of BMs before starting nivolumab, and the other cohort's BMs were untreated before starting nivolumab. The intracranial response rate of nivolumab was 12% in the cohort of patients with untreated BMs; however, patients who had BMs >1 cm or those who had multiple BMs had a 0% ORR. Therefore, patients who have clear cell RCC with BMs should receive upfront BM-directed therapy before initiating or changing systemic therapy.

10970142, 2020, 7, Downloaded from https://acsjournals.onlinelibrary.wiley.com/doi/10.1002/cncr.32714, Wiley Online Library on [03/02/2026]. See the Terms and Conditions (https://onlinelibrary.wiley.com/terms-and-conditions) on Wiley Online Library for rules of use; OA articles are governed by the applicable Creative Commons License

Other Primary Histologies

ICI therapies have been approved by the US Food and Drug Administration for the treatment of multiple solid tumor histologies in the locally advanced, metastatic, and/or recurrent setting. As a result, there is increased interest in the utility of these agents to treat patients who have untreated BMs; however, currently, there are few data to support this approach outside of a clinical trial.[52] Therefore, patients with untreated BMs from primary histologies other than those described above should receive upfront BM-directed therapy before initiating or changing systemic therapy until further data are available.

Summary on Systemic Therapies

Evidence demonstrating the intracranial activity of systemic agents for patients who have melanoma, NSCLC, and breast cancer with BMs is exciting, yet the optimal sequencing of therapies remains unknown. It is likely to be patient-specific and to depend on a combination of patient factors (symptomatic/asymptomatic), BM histology, tumor genetics, volume of intracranial disease, previous systemic therapies, and the type of systemic therapy proposed. Some argue that upfront systemic therapy in these patients addresses patients' intracranial and extracranial disease while also potentially sparing them from the neurotoxic effects of radiation therapy (RT) until intracranial disease progression. Others maintain that the risk of neurotoxicity from SRS is low and that BM-directed therapy earlier in the course of treatment or, in the case of immunotherapy, combined with systemic therapy may result in better outcomes.[53-57] Similar optimism existed for upfront the treatment of patients with BMs using EGFR-TKi therapy; however, a large, multi-institutional, retrospective study found that upfront SRS was independently associated with improved OS compared with upfront EGFR-TKi therapy.[41] Further research is required to better determine the efficacy and toxicity of combining immunotherapy with SRS and the optimal sequencing of treatment modalities. In addition, future studies should focus on identifying patient and disease factors that influence treatment sequence. Currently, it is recommended that patients with BMs who are candidates for systemic therapies that have demonstrated intracranial activity should be discussed in a multidisciplinary setting to determine the optimal integration of therapies.

THE ROLE OF RT FOR UNTREATED BRAIN METASTASES

Whole-Brain Radiation Therapy

WBRT was typically used for patients with BMs who were not surgical candidates. WBRT is palliative, temporarily halting BM growth and gradually reducing mass effect and associated neurologic symptoms. Compared with SRS or surgery alone, WBRT significantly reduces the treated metastasis recurrence rate and the rate of new disease throughout the brain.[30,58-62] Importantly, the addition of WBRT to either SRS or surgery has not been shown to increase OS, and substantial risks of long-term BM recurrence and neurologic death remain.[30,58-62] The most common WBRT regimen is 10 daily doses of 300 centigrays (cGy), although numerous dose and fractionation schemes have been reported.[63] Interestingly, an analysis of a recent phase 3 trial of WBRT in brain metastasis suggests that ten 300-cGy fractions may be superior to fifteen 250-cGy fractions.[64] Attempts to improve WBRT's treated metastasis control by combining systemic agents have demonstrated increased intracranial response rates, although with minimal, if any, survival benefit and increased AEs.[65] Because of a lack of high-level evidence regarding the toxicity of concurrent systemic therapies with WBRT, they are typically delivered sequentially to avoid neurotoxicity.

SRS With or Without WBRT

SRS as a treatment modality for BMs was established in a cooperative group trial as a means of treating patients with previously irradiated primary and secondary brain tumors with acceptable toxicity.[66] Trials investigating the addition of SRS to WBRT versus WBRT alone demonstrated improved local control, with no difference in OS between the 2 groups.[67,68] WBRT plus SRS, however, yields decreased QoL compared with SRS alone, with long-term survivors demonstrating a higher incidence of cognitive deterioration at 3 and 12 months.[59,60] Most studies only included patients with a limited size (<4 cm) and number (1-4) of BMs, so the benefit of omitting WBRT in patients with >4 BMs is unclear. A prospective, observational, noninferiority study (Stereotactic Radiosurgery for Patients With Multiple Brain Metastases [JLGK0901]) enrolled newly diagnosed patients who had a good PS and 1 to 10 BMs (largest tumor, <10 cm^3; aggregate tumor volume, ≤15 cm^3) to receive SRS to all BMs; a noninferior median OS was demonstrated for patients who had 5 to 10 BMs versus 2 to 4 BMs, and no difference in treatment-related AE rates was observed (see Figs. 1 and 2).[69] The results of that study support consideration of SRS alone for patients with a good PS and 1 to 10 untreated BMs who meet JLGK0901 inclusion criteria; however it should be noted that only 17% of patients on that study had 5 to 10 BMs, and the median number was 6 BMs. Importantly, the study did not

10970142, 2020, 7, Downloaded from https://acsjournals.onlinelibrary.wiley.com/doi/10.1002/cncr.32714, Wiley Online Library on [03/02/2026]. See the Terms and Conditions (https://onlinelibrary.wiley.com/terms-and-conditions) on Wiley Online Library for rules of use; OA articles are governed by the applicable Creative Commons License

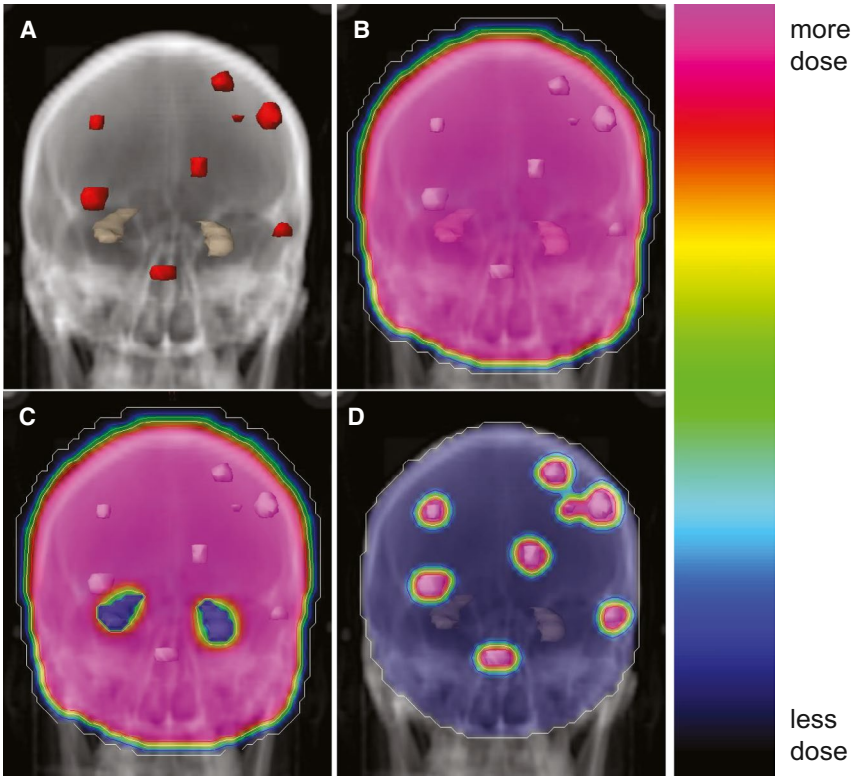

Figure 1. (A) Illustration of brain metastases (red) and hippocampi (brown). (B-D) Illustration of high-dose areas for various treatment strategies including whole-brain radiation therapy (B), hippocampal-avoidance whole brain radiation therapy (C), and single-isocenter multi-target radiosurgery (D).

compare WBRT versus SRS, and the superiority of SRS versus WBRT (and vice versa) has not been established in the setting of ≥5 BMs. To address this question, there is currently a phase 3 cooperative group trial (clinicaltrials.gov identifier NCT03550391) comparing WBRT with SRS in patients who have 5 to 15 BMs with the primary endpoints of both OS and neurocognitive PFS.

Patients With a Poor Prognosis/ Performance Status

Aggressive BM treatment with surgery and/or SRS is not recommended in patients who have a poor prognosis or PS, and WBRT is generally preferred, although there is no strong evidence of improved survival with RT compared with best supportive care. Randomized controlled trials comparing best supportive care with WBRT and best supportive care in patients with BMs showed questionable benefit.[70,71] A noninferiority study comparing WBRT and best supportive care with best supportive care alone in patients who had NSCLC with BMs but were ineligible for SRS or surgery showed no significant difference in the median OS or QoL, but failed to show noninferiority of quality-adjusted life-years for best supportive care.[71] The authors concluded, however, that WBRT was not justified because of the lack of improvement in OS or QoL, despite the small benefit in quality-adjusted life-years. Whether these results are applicable to all patients with BMs is unclear. Therefore, the decision to offer WBRT to these patients should be made on an individual basis, after a thorough discussion with the patient of the potential benefits and toxicity, while recognizing the lack of evidence supporting a clear benefit over best supportive care alone. Treatment algorithms depicting our institutional practice for the initial management of patients with BM have been provided in the symptomatic (Fig. 2) and asymptomatic (Fig. 3) settings.

INNOVATIONS IN RADIATION ONCOLOGY

Numerous technological advancements have reshaped how radiation is used for patients with BMs. Specifically, innovations in patient immobilization, target localization, and treatment delivery have improved the process and logistics for SRS, which is now the radiation modality of choice for many patients with BMs. Initially, SRS required an uncomfortable, surgically fixed head

10970142, 2020, 7, Downloaded from https://acsjournals.onlinelibrary.wiley.com/doi/10.1002/cncr.32714, Wiley Online Library on [03/02/2026]. See the Terms and Conditions (https://onlinelibrary.wiley.com/terms-and-conditions) on Wiley Online Library for rules of use; OA articles are governed by the applicable Creative Commons License

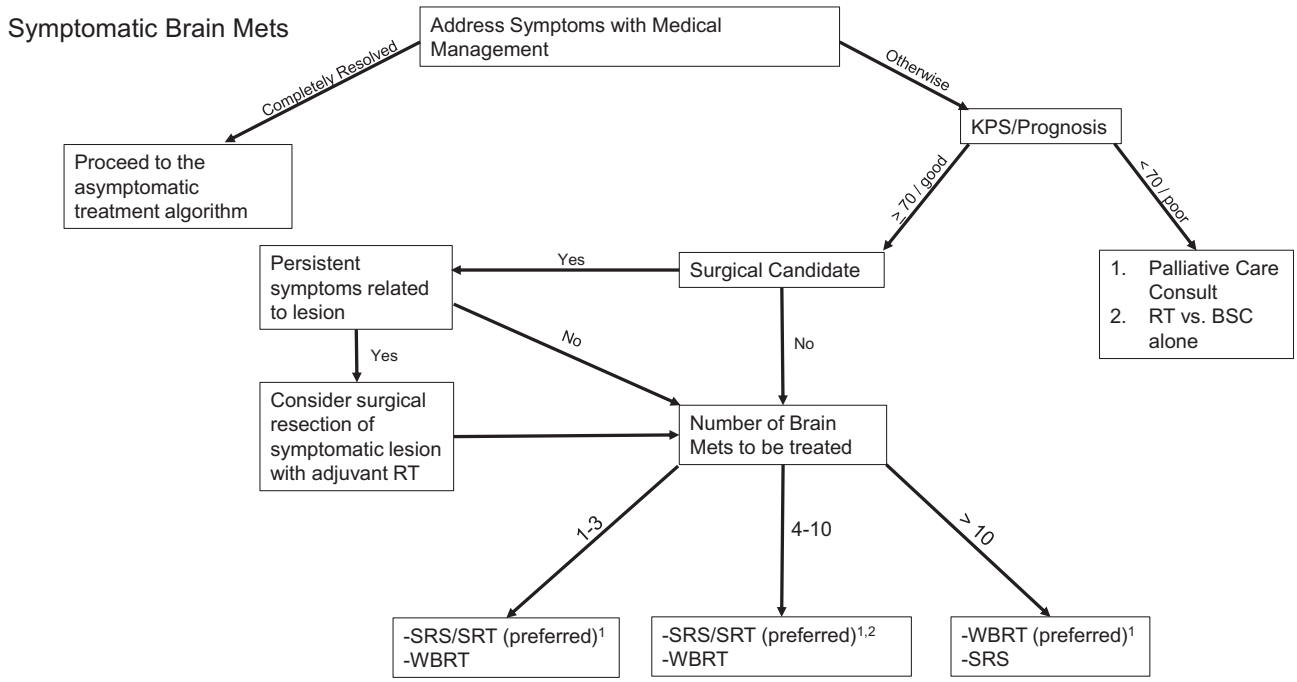

[1]Preferred reflects the authors' opinion
[2]If patient meets entry criteria of JLGK0901 trial

Figure 2. The proposed treatment algorithm for patients with symptomatic brain metastases and a known cancer diagnosis is shown. BSC indicates best supportive care; JLGK0901 trial, a prospective, observational, noninferiority trial of stereotactic radiosurgery for patients with multiple brain metastases[69]; KPS, Karnofsky performance status; Mets, metastases; RT, radiation therapy; SRS, stereotactic radiosurgery; SRT, stereotactic radiation therapy; WBRT, whole-brain radiation therapy.

frame; however, now, custom-molded thermoplastic head masks and image-based guidance can be used, resulting in setup accuracy equivalent to that of frame-based systems and facilitating both SF-SRS and HF-SRS. HF-SRS uses the same patient setup, immobilization, dose planning, and delivery techniques as SF-SRS, but it delivers the total dose over multiple fractions (often 3-5 fractions), thereby potentially reducing the risk to normal tissues by allowing DNA damage repair. This is important because SF-SRS requires dose reductions to treat larger target volumes (>3 cm) to minimize toxicity. Retrospective studies suggest that HF-SRS provides excellent control of large BMs (>2 cm) and resection cavities with a low radionecrosis rate.[72,73] Further insight will be gained when the results of the ongoing phase 3 cooperative group trial (clinicaltrials.gov identifier NCT04114981) comparing SF-SRS versus fractionated SRS (3-5 sessions) for resected BM are released. Currently, we typically use HF-SRS for lesions that are >3 cm in size and/or when normal tissue constraints cannot be met using SF-SRS. Another promising radiation technique for patients with multiple BMs is single-isocenter multitarget (SIMT) SRS, allowing for the simultaneous delivery of SRS to multiple BMs. Previously, delivering SF-SRS to patients with ≥5 BMs was challenging because of the long treatment times required for sequential treatment, a challenge that is overcome by SIMT SRS. When analyzed retrospectively, 1 study found that patients with ≥4 BMs who underwent SIMT SF-SRS had a crude 11.6% treated-tumor progression rate, although the authors postulate that SIMT HF-SRS may improve clinical outcomes and radiation-related toxicity.[74]

INNOVATIONS IN SURGICAL THERAPIES

Laser interstitial thermal therapy (LITT) uses focal laser energy delivered through a small fiberoptic catheter to cause interstitial hyperthermia and coagulate surrounding tissue and has been used increasingly to treat patients with primary and secondary brain tumors.[75-81] Currently, there are 2 technologies used commonly for LITT, and the specific differences between the 2 systems are beyond the scope of this discussion. In general, the maximum radius of tumor-cell kill that can be elicited by a single fiber is from 1.5 to 2.0 cm, making the maximal treatable lesion dimension, by 1 trajectory, from 3.0 to

10970142, 2020, 7, Downloaded from https://acsjournals.onlinelibrary.wiley.com/doi/10.1002/cncr.32714, Wiley Online Library on [03/02/2026]. See the Terms and Conditions (https://onlinelibrary.wiley.com/terms-and-conditions) on Wiley Online Library for rules of use; OA articles are governed by the applicable Creative Commons License

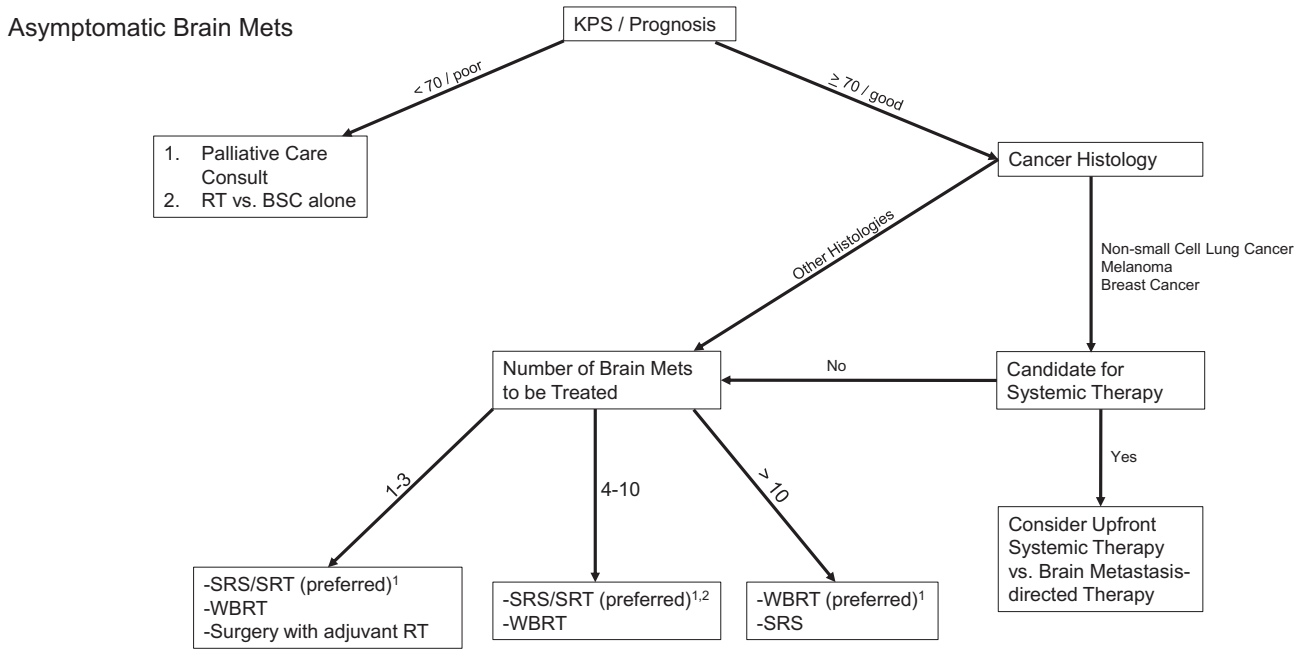

[1]Preferred reflects the authors' opinion
[2]If patient meets entry criteria of JLGK0901 trial

Figure 3. The proposed treatment algorithm for patients with asymptomatic brain metastases and a known cancer diagnosis. BSC indicates best supportive care; JLKG0901 trial, a prospective, observational, noninferiority trial of stereotactic radiosurgery for patients with multiple brain metastases[69]; KPS, Karnofsky Performance Status; Mets, metastases; RT, radiation therapy; SRS, stereotactic radiosurgery; SRT, stereotactic radiation therapy; WBRT, whole-brain radiation therapy.

4.0 cm. Surgical considerations, much like biopsy, center about fashioning a safe trajectory into the relevant lesion and minding borders with eloquent areas. Considerations specific to LITT include proximity to "water"-containing structures, such as large blood vessels and ventricles, which can act as heat sinks and possibly makes killing along their borders less efficient. Other considerations include the initial edema that will result from thermal ablation. Edema does frequently resolve in ensuing days to weeks, but the initial treatment-induced swelling must be considered.

In the setting of potentially recurrent BMs previously treated with SRS, LITT is an attractive treatment option because it is minimally invasive, and biopsies can be obtained as part of the procedure for histopathologic diagnosis before delivery, which can guide subsequent oncologic care.[82,83] LITT is effective at treating recurrent BMs and radionecrosis, has the potential to treat BMs not amenable to surgical resection, and can be used in patients who are not candidates for craniotomies secondary to medical comorbidities.[84,85] Retrospective studies of LITT in patients with recurrent BMs after SRS have reported treated metastases control rates of 60% to 100%.[86-88] One multi-institutional retrospective analysis found that all instances of recurrence occurred in patients who received LITT in which <80% of the lesion was ablated.[88] Interestingly, a subset of patients also received HF-SRS (25 Gray in 5 fractions) to the treatment area after LITT, in which no patients demonstrated progression of their treated metastasis, despite some lesions having been treated with an ablation efficiency <80%, suggesting that adjuvant RT may enhance the efficacy of LITT. In our practice, we consider LITT for patients who have imaging findings concerning for BM recurrence after treatment with SRS. Biopsies are taken as part of the procedure and, if active cancer is found, then post-LITT HF-SRS to the treatment area is recommended (25 Gray in 5 fractions), typically 2 to 3 weeks after LITT. If the biopsy demonstrates radionecrosis alone, then LITT alone is considered to be sufficient.

SURVEILLANCE IMAGING AND ASSESSING TREATMENT RESPONSE

The frequency of brain imaging depends on the treatment course that the patient received for their BMs. Similar to their initial staging, we recommend surveillance imaging with a thin-cut (≤1.5 mm) brain

10970142, 2020, 7, Downloaded from https://acsjournals.onlinelibrary.wiley.com/doi/10.1002/cncr.32714, Wiley Online Library on [03/02/2026]. See the Terms and Conditions (https://onlinelibrary.wiley.com/terms-and-conditions) on Wiley Online Library for rules of use; OA articles are governed by the applicable Creative Commons License

MRI with and without intravenous gadolinium contrast, unless contraindicated, in which case a thin-cut (<1.5 mm) CT scan with and without contrast is recommended. For patients who are to receive upfront systemic therapy for their active intracranial disease, we recommend surveillance imaging within 1 month of initiating systemic therapy with subsequent scans every 6 weeks until 12 weeks, then every 9 weeks until 48 weeks, then every 3 months, or as clinically indicated.[43,44] For patients receiving SRS in either the intact or adjuvant setting, surveillance imaging should occur every 2 to 3 months, depending on specific patient and disease factors, for the first year before increasing the interval to 4 to 6 months.[89] For patients undergoing WBRT in either the intact or adjuvant setting, surveillance imaging should occur every 3 months for the first year before increasing the interval to 4 to 6 months.

To better standardize the reporting of treatment response and progression of BMs in clinical trials, imaging criteria and the minimum requirements for brain imaging were developed by the Response Assessment in Neuro-Oncology Brain Metastases (RANO-BM) Working Group.[90-92] These criteria predominately use changes in tumor size to determine treatment response. Because early changes in tumor size do not always correlate with outcome, serial imaging of patients is required to elucidate treatment response most accurately. After treatment, assessment of target lesion(s) on standard MRI may be confounded by imaging changes resulting from treatment effect. The RANO-BM Working Group recommends 1 or more of the following methods to gather further information: 1) repeating the brain imaging (possibly in a shorter interval), 2) surgical pathology, and/or 3) advanced imaging techniques, such as perfusion MRI, magnetic resonance spectroscopy, or fluorothymidine F-18 or fluorodeoxyglucose-PET imaging. Review of these cases in a multidisciplinary setting and use of clinical judgement also are recommended because of the paucity of literature suggesting that 1 standard approach is best for all patients.

RADIATION THERAPY SIDE EFFECTS

RT-related CNS side effects are grouped into 3 categories: early/acute, early delayed, or late. Early/acute side effects occur with treatment up to 6 weeks post-RT, and the most common are fatigue, alopecia, mild scalp erythema, and pruritus, with the severity of symptoms mostly grade 1 and 2 for both WBRT and SRS.[58,67] More severe acute toxicity is generally infrequent for both SRS and WBRT, with fatigue in 2.2% to 5.4% of patients and skin toxicity in 1% to 3%.[30,59] Ear fullness and hearing loss are less common, affecting approximately 1% to 2% of patients,[30,59,67] whereas increased neurologic symptoms, likely from cerebral edema, can occur in as much as 5% to 10% of patients.[67] Early delayed side effects occur from 6 weeks to 6 months post-RT and consist of fatigue and decreased neurocognitive function, with recent data indicating cognitive deterioration rates of 50% in patients who receive SRS, and the addition of WBRT raises this to 72%.[59] Late side effects occur >6 months post-RT and include radionecrosis, decreased neurocognitive function, with rates approaching 60% at 12 months for patients who receive SRS, and 95% with the addition of WBRT.[59] Other, rarer, late side effects include neuroendocrine dysfunction, cerebrovascular effects, and secondary malignancy, although many patients who receive WBRT do not survive long enough to experience these late side effects.

Considerable interest exists in mitigating the neurocognitive toxicity associated with WBRT while permitting the effective treatment of numerous BMs.[93] A randomized trial comparing WBRT plus memantine (WBRT + M) or placebo found that memantine significantly increased the time to cognitive decline, with higher performance in many of the other neuropsychological tests administered, although the trial did not achieve its prespecified endpoint.[12] Nonetheless, memantine should be considered for patients who have a good prognosis (>6 months) with BMs requiring WBRT. Other neuroprotectants have been reported,[94] and others are being actively explored (clinicaltrials.gov identifier NCT03608020).

There have also been technical improvements in the administration of WBRT. For patients who have >4 BMs and a good prognosis, hippocampal-avoidance WBRT (HA-WBRT) provides another option for reducing neurocognitive dysfunction. There have been technical improvements in the administration of WBRT. For patients who have >4 BM and a good prognosis, HA-WBRT is an interesting option. HA-WBRT limits the dose delivered to the hippocampi using intensity-modulated RT. A multicenter, prospective, single-arm, phase 2 trial consisting of 113 patients with BMs who received HA-WBRT resulted in less relative decline in 4-month Hopkins Verbal Learning Test-Revised Delayed Recall scores than in the historically reported scores for WBRT.[95] A recent abstract from a phase 3 cooperative group trial (NRG-CC001; Memantine Hydrochloride and Whole-Brain Radiotherapy With or Without

10970142, 2020, 7, Downloaded from https://acsjournals.onlinelibrary.wiley.com/doi/10.1002/cncr.32714, Wiley Online Library on [03/02/2026]. See the Terms and Conditions (https://onlinelibrary.wiley.com/terms-and-conditions) on Wiley Online Library for rules of use; OA articles are governed by the applicable Creative Commons License

Hippocampal Avoidance in Reducing Neurocognitive Decline in Patients With Brain Metastases; clinicaltrials.gov identifier NCT02360215) comparing traditional WBRT + M with or without hippocampal avoidance indicates that HA-WBRT + M yields a significantly lower risk of neurocognitive function failure at 6 and 12 months without compromising survival or intracranial disease control versus WBRT + M.[96,97] As discussed above earlier, SIMT provides another means for limiting the dose to normal neural structures in patients with multiple BMs, potentially reducing the neurocognitive impact of RT (Fig. 3). A prospective trial (clinicaltrials.gov identifier NCT02886572) is near completion at our institution evaluating the efficacy and toxicity of SIMT in patients who have 4 to 10 BMs. Importantly, a phase 3 cooperative group trial is now recruiting that will compare HA-WBRT plus memantine versus SIMT for neurocognitive function (clinicaltrials.gov identifier NCT03550391); however, to date, no data are yet available comparing the neurocognitive effect of these modalities. Until the results from that study are known, choosing the appropriate technique requires thoughtful consideration of their potential advantages and limitations (Table 1).

Radionecrosis is a serious late complication after high-dose cranial irradiation, generally occurring near the target. The symptomatic radionecrosis rate after SRS is approximately 10%, with asymptomatic radionecrosis rates as high as 50%, depending on the volume of brain irradiated.[98] The true post-SRS radionecrosis rate remains poorly defined because the appearance of radionecrosis is similar to that of tumor recurrence on contrast-enhanced MRIs, and studies have not always confirmed radionecrosis pathologically. For imaging findings concerning for treated metastasis progression after SRS, short-interval follow-up MRI (4-8 weeks) is recommended, assuming that decreasing lesion size and/or improving edema are more consistent with radionecrosis; however, conventional MR features have poor predictive value. A recent retrospective study of patients undergoing biopsy because of radiographic findings concerning for recurrence of previously irradiated BMs found that the timing of biopsy after SRS delivery was associated with the biopsy result on multivariate analysis.[99] For patients who were biopsied within 9 months of SRS, 47% had radionecrosis identified, whereas 94% of patients who were biopsied >9 months after SRS demonstrated radionecrosis.

As a result, other MRI techniques have been investigated to better distinguish between radionecrosis

TABLE 1. Pros and Cons of Radiation Delivery Techniques for Patients With Multiple Brain Metastases

	WBRT	HA-WBRT	SIMT SRS
Pros	• Better distant CNS control than SRS alone • Easier treatment planning • Entire brain treated • No BM number limit • Less treatment time • Easier patient setup • Treatment planning MRI not required	• Better distant CNS control than SRS alone • Less neurocognitive decline compared with WBRT or WBRT + memantine	• Improved TMC • Delivered over 1-5 d • Decreased dose to normal brain • Avoids hippocampi • Less neurocognitive function decline vs WBRT
Cons	• Decreased neurocognitive function • Decreased TMC vs SRS • Delivered over 1-2 wk	• Decreased TMC vs SRS • Delivered over 2 wk • Hippocampi remain possible sites for CNS progression • Patients with metastases ≤5 mm around hippocampi not eligible • Complex treatment planning • Treatment planning requires MRI • Challenges with insurance coverage • Increased daily treatment delivery time vs WBRT	• Increased rate of new CNS metastases • Complex treatment planning • Requires advanced technology • Increased daily treatment delivery time vs WBRT • Complex patient setup • Complex treatment planning • Treatment planning requires MRI • Challenges with insurance coverage

Abbreviations: BM, brain metastases; CNS, central nervous system; HA-WBRT, hippocampal-avoidance whole-brain radiation therapy; HF-SRS, hypofractionated stereotactic radiosurgery; MRI, magnetic resonance imaging; SIMT, single-isocenter multi-target; SRS, stereotactic radiosurgery; TMC, treated metastasis control; WBRT, whole-brain radiation therapy.

10970142, 2020, 7, Downloaded from https://acsjournals.onlinelibrary.wiley.com/doi/10.1002/cncr.32714, Wiley Online Library on [03/02/2026]. See the Terms and Conditions (https://onlinelibrary.wiley.com/terms-and-conditions) on Wiley Online Library for rules of use; OA articles are governed by the applicable Creative Commons License

and recurrent BMs, such as MR spectroscopy (in particular, chemical exchange saturation transfer) and perfusion-weighted MRI to evaluate relative cerebral blood volume and intravoxel incoherent motion, with variable success.[100-103] Nuclear medicine imaging has also been used to help identify active tumor versus radionecrosis, with particular interest in the use of amino acid tracers in PET-CTs.[98,100] Most studies, however, are small and often do not include pathologic confirmation, making it difficult to determine their true accuracy. In addition, many of these studies examined the independent use of these modalities, yet more recent studies suggest that combining these modalities increases their power.[100] Currently, using multiple imaging techniques is clinically impractical because of the increased cost and time required. Unfortunately, no consensus exists regarding which imaging modalities are best at distinguishing radionecrosis from tumor recurrence; however, it is extremely important because further RT therapy may benefit patients with disease recurrence, whereas it is typically contraindicated for radionecrosis. Therefore, in patients for whom there is diagnostic uncertainty, tissue confirmation should be pursued, if possible, before determining the optimal treatment.

Radionecrosis is often self-limiting, and asymptomatic lesions can be managed with observation alone. Corticosteroids are the primary treatment for symptomatic radionecrosis, ameliorating perilesional edema. The initial steroid dose depends on symptom severity (2-8 mg of dexamethasone daily) and can be slowly tapered over several weeks after symptom resolution. For steroid-refractory radionecrosis, noninvasive therapies such as anticoagulants, vitamin-E/pentoxifylline, hyperbaric oxygen therapy, and bevacizumab can be considered.[98] Two randomized clinical trials demonstrated improved clinical and radiographic responses with bevacizumab compared with placebo or steroids, with low toxicity rates.[98,104] Optimal timing, dosing, duration of bevacizumab for radionecrosis remains unknown, and further studies are required to identify patients who would benefit most from this therapy, and variability in indications for primary tumor types makes firm recommendations difficult. The advent of biosimilar options could also open new opportunities. We therefore recommend treatment decisions based on an individual patient's situation, in the absence of open clinical trials and more data.

Severe radionecrosis, refractory to conservative management and/or with diagnostic uncertainty, may necessitate surgical intervention. Resection can provide symptomatic relief by alleviating mass effect, edema, and possibly decreasing steroid dose, while also providing tissue confirmation. Surgery, however, can result in considerable morbidity, increasing the importance of appropriate patient selection.[105]

Recently, LITT has been investigated as a treatment for radionecrosis.[82-84,87,106] LITT is an attractive option for patients with radionecrosis as it is minimally invasive, tissue can be obtained to support the diagnosis, and patients not amenable to surgical resection can potentially be treated.[107] In the largest retrospective analysis of LITT for patients with biopsy-proven RN, the average post-LITT survival and PFS in patients with previously treated BM was 19.2 months and 11.4 months, respectively.[106] Patients reported improved mental health and vitality after LITT, with no toxicity reported. In a multicenter, prospective study, 91% of patients demonstrated no lesion progression at last follow-up and had an OS of 82.1% at 26 weeks.[87] Improvements in social and emotional well-being at 12-16 weeks were also noted, with 10.5% of patients experiencing AEs. Importantly, 31% of steroid-dependent patients were able to reduce their steroid requirement or stop completely by 12 weeks. In our practice, patients with symptomatic, steroid-refractory, suspected radionecrosis are considered for LITT, with a biopsy performed as part of the procedure to confirm radionecrosis before delivering therapy. Should active tumor be present, patients receive HF-SRS to the treatment area after LITT, as previously described.

FUTURE DIRECTIONS

There is great interest in whether BMs harbor genetic differences from primary tumors and how these differences can be exploited to improve outcome. Massively parallel DNA sequencing of a primary tumor and BMs from an inflammatory patient with breast cancer patient found 2 de novo mutations and a large deletion in the BMs absent from the primary tumor.[108] Whole-exome sequencing (performed on BMs, primary tumors, and normal tissue of various histologies) found a branched pattern of evolution between BMs and the primary, suggesting a common ancestor undergoing independent evolution.[109] In >50% of cases, potentially clinically meaningful genetic alterations were noted in BMs, but not in the primary, potentially guiding BM-targeted therapies. In addition, multiple BMs from the same patient exhibited shared mutations that were absent from the primary (including significant driver alterations) suggesting intracranial genetic *homogeneity*. Surprisingly, lymph nodes and extracranial metastases

10970142, 2020, 7, Downloaded from https://acsjournals.onlinelibrary.wiley.com/doi/10.1002/cncr.32714, Wiley Online Library on [03/02/2026]. See the Terms and Conditions (https://onlinelibrary.wiley.com/terms-and-conditions) on Wiley Online Library for rules of use; OA articles are governed by the applicable Creative Commons License

TABLE 2. Selected Ongoing Clinical Trials in the Treatment of Patients With Brain Metastases

Study	Phase	Country	Histology	No. of BMs	Arm 1	Arm 2	Primary Outcomes
NCT04114981	3	United States	Solid tumors except: small-cell tumors, leukemia, lymphoma, myeloma	1 Resected, ≤3 intact	SF-SRS	HF-SRS (3 or 5)	Surgical bed recurrence-free survival
NCT03741673	3	United States	Solid tumors except: germ-cell tumors, small-cell tumors, lymphoma	Not reported; 7 cm in size	Preoperative SRS	Postoperative SRS	1-Year leptomeningeal disease-free rate
NCT03550391	3	Canada, United States	Solid tumors except: germ-cell tumors, small-cell tumors, lymphoma	5-15 Intact	HA-WBRT + memantine	SF-SRS	1) Overall survival; 2) neurocognitive PFS
NCT03608020	1/2	United States	Solid tumors except: germ-cell tumors, small-cell tumors, lymphoma	>10 Intact	WBRT + BMX-001 (manganese butoxyethyl pyridyl porphyrin)	WBRT	1) Assess safety and tolerability of WBRT + BMX-001; 2) compare neurocognition
NCT03769103	2	Canada	Treatment-naive, *EGFR*-positive NSCLC	1-10 Intact	Osimertinib	SRS → osimertinib	Intracranial PFS
NCT03340129	2	Australia	Melanoma	≥1	Nivolumab + ipilimumab	Nivolumab + ipilimumab + concurrent SF-SRS or HF-SRS	Neurologic-specific cause of death

Abbreviations: BMs, brain metastases; EGFR, epidermal growth factor receptor; HA-WBRT, hippocampal-avoidance whole-brain radiation therapy; HF-SRS, hypofractionated stereotactic radiosurgery; NCT, clinicaltrials.gov identifier; NSCLC, non–small-cell lung cancer; PFS, progression-free survival; SF-SRS, single fraction stereotactic radiosurgery; SRS, stereotactic radiosurgery; WBRT, whole-brain radiation therapy.

were genetically divergent compared with BMs, indicating that extracranial disease sites are poor surrogates for BMs. Studies reveal an increased frequency of targetable genetic aberrations in BMs compared with extracranial disease for multiple cancer histologies.[110] Thus, analyses of BMs may identify targetable mutations not present in the primary and, if available, should be considered for targeted therapy, although the significance of these findings and how best to target divergent mutations requires further investigation.

Conclusion

Numerous advancements in neurosurgery, medical oncology, radiology, tumor biology, and radiation oncology have resulted in the capacity for more effective and personalized approaches to patients with BMs. Despite these advances, many questions remain about patient selection and ideal therapy sequencing. As a result, timely discussions of the care for these patients in a multidisciplinary setting and enrollment in ongoing clinical trials (Table 2) are essential for optimal management.

FUNDING SUPPORT

No specific funding was disclosed.

CONFLICT OF INTEREST DISCLOSURES

Peter E. Fecci reports research funding and personal fees from Monteris outside the submitted work. Carey K. Anders reports clinical trials support from Eli Lilly, G1-Therapeutics, Merck & Company, Nektar, PUMA, Seattle Genetics, and Tesaro; and personal fees from Eisai, Genentech/Roche, Ipsen, and PUMA, all outside the submitted work. Jeffrey M. Clarke reports research funding and nonfinancial support from Bristol-Myers Squibb outside the submitted work; research funding, personal fees, and nonfinancial support from Eli Lilly outside the submitted work; research funding from AbbVie, Adaptimmune, Array, Bayer, Bristol-Myers Squibb, Eli Lilly, Genentech, GlaxoSmithKline, Medpacto, Moderna, and Spectrum; personal fees, nonfinancial support, and travel expenses from Eli Lilly, Guardant, and Merck & Company; personal fees from Achilles Therapeutics; and serves on the Lung Cancer Initiative of North Carolina board of directors (uncompensated), all outside the submitted work. April K. S. Salama reports personal fees from Array and Bristol-Myers Squibb and institutional research funding from Bristol-Myers Squibb, Celldex, Dynavax, Immunocore, Merck & Company, and Reata, all outside the submitted work. Justus D. Adamson reports ownership interest in Clearsight RT, LLC. John H. Sampson reports grants and personal fees from Annias Immunotherapeutics; owns equity in Immunomic Therapeutics and Insera Health; owns intellectual property with Celldex; and patents with Instarl and Neuronium, all during the course of the study. John P. Kirkpatrick reports research funding from Varian Medical Systems outside the submitted work and ownership interest in Clearsight RT, LLC. The remaining authors made no disclosures.

REFERENCES

1. Fox BD, Cheung VJ, Patel AJ, Suki D, Rao G. Epidemiology of metastatic brain tumors. *Neurosurg Clin North Am*. 2011;22:1-6.
2. Nayak L, Lee EQ, Wen PY. Epidemiology of brain metastases. *Curr Oncol Rep*. 2012;14:48-54.
3. Schellinger PD, Meinck HM, Thron A. Diagnostic accuracy of MRI compared to CCT in patients with brain metastases. *J Neurooncol*. 1999;44:275-281.

10970142, 2020, 7, Downloaded from https://acsjournals.onlinelibrary.wiley.com/doi/10.1002/cncr.32714, Wiley Online Library on [03/02/2026]. See the Terms and Conditions (https://onlinelibrary.wiley.com/terms-and-conditions) on Wiley Online Library for rules of use; OA articles are governed by the applicable Creative Commons License

4. Sze G, Milano E, Johnson C, Heier L. Detection of brain metastases: comparison of contrast-enhanced MR with unenhanced MR and enhanced CT. *AJNR Am J Neuroradiol*. 1990;11:785-791.
5. Nagai A, Shibamoto Y, Mori Y, Hashizume C, Hagiwara M, Kobayashi T. Increases in the number of brain metastases detected at frame-fixed, thin-slice MRI for gamma knife surgery planning. *Neuro Oncol*. 2010;12:1187-1192.
6. Okubo T, Hayashi N, Shirouzu I, et al. Detection of brain metastasis: comparison of Turbo-FLAIR imaging, T2-weighted imaging and double-dose gadolinium-enhanced MR imaging. *Radiat Med*. 1998;16:273-281.
7. Mehrabian H, Detsky J, Soliman H, Sahgal A, Stanisz GJ. Advanced magnetic resonance imaging techniques in management of brain metastases. *Front Oncol*. 2019;9:440.
8. Achrol AS, Rennert RC, Anders C, et al. Brain metastases. *Nat Rev Dis Primers*. 2019;5:5.
9. Pope WB. Brain metastases: neuroimaging. In: Schiff D, van den Bent MJ, eds. Handbook Clin Neurolology. 3rd Series. Volume 149: Metastatic Disease of the Nervous System. Elsevier; 2018:89-112.
10. Zimm S, Wampler GL, Stablein D, Hazra T, Young HF. Intracerebral metastases in solid-tumor patients: natural history and results of treatment. *Cancer*. 1981;48:384-394.
11. Mehta MP, Rodrigus P, Terhaard CH, et al. Survival and neurologic outcomes in a randomized trial of motexafin gadolinium and whole-brain radiation therapy in brain metastases. *J Clin Oncol*. 2003;21:2529-2536.
12. Brown PD, Pugh S, Laack NN, et al. Memantine for the prevention of cognitive dysfunction in patients receiving whole-brain radiotherapy: a randomized, double-blind, placebo-controlled trial. *Neuro Oncol*. 2013;15:1429-1437.
13. Stelzer KJ. Epidemiology and prognosis of brain metastases. *Surg Neurol Int*. 2013;4(suppl 4):S192-S202.
14. Sperduto PW, Jiang W, Brown PD, et al. Estimating survival in melanoma patients with brain metastases: an update of the Graded Prognostic Assessment for Melanoma Using Molecular Markers (Melanoma-molGPA). *Int J Radiat Oncol Biol Phys*. 2017;99:812-816.
15. Sperduto PW, Yang TJ, Beal K, et al. Estimating survival in patients with lung cancer and brain metastases: an update of the Graded Prognostic Assessment for Lung Cancer Using Molecular Markers (Lung-molGPA). *JAMA Oncol*. 2017;3:827-831.
16. Temel JS, Greer JA, Muzikansky A, et al. Early palliative care for patients with metastatic non-small-cell lung cancer. *N Engl J Med*. 2010;363:733-742.
17. Vecht CJ, Hovestadt A, Verbiest HB, van Vliet JJ, van Putten WL. Dose-effect relationship of dexamethasone on Karnofsky performance in metastatic brain tumors: a randomized study of doses of 4, 8, and 16 mg per day. *Neurology*. 1994;44:675-680.
18. Arbour KC, Mezquita L, Long N, et al. Impact of baseline steroids on efficacy of programmed cell death-1 and programmed death-ligand 1 blockade in patients with non-small-cell lung cancer. *J Clin Oncol*. 2018;36:2872-2878.
19. Ricciuti B, Dahlberg SE, Adeni A, Sholl LM, Nishino M, Awad MM. Immune checkpoint inhibitor outcomes for patients with non-small-cell lung cancer receiving baseline corticosteroids for palliative versus nonpalliative indications. *J Clin Oncol*. 2019;37:1927-1934.
20. Scott SC, Pennell NA. Early use of systemic corticosteroids in patients with advanced NSCLC treated with nivolumab. *J Thorac Oncol*. 2018;13:1771-1775.
21. Mikkelsen T, Paleologos NA, Robinson PD, et al. The role of prophylactic anticonvulsants in the management of brain metastases: a systematic review and evidence-based clinical practice guideline. *J Neurooncol*. 2010;96:97-102.
22. Tremont-Lukats IW, Ratilal BO, Armstrong T, Gilbert MR. Antiepileptic drugs for preventing seizures in people with brain tumors. *Cochrane Database Syst Rev*. 2008;2:CD004424.
23. Greenhalgh J, Weston J, Dundar Y, Nevitt SJ, Marson AG. Antiepileptic drugs as prophylaxis for postcraniotomy seizures. *Cochrane Database Syst Rev*. 2018;5:CD007286.
24. Soon YY, Tham IWK, Lim KH, Koh WY, Lu JJ. Surgery or radiosurgery plus whole brain radiotherapy versus surgery or radiosurgery alone for brain metastases. *Cochrane Database Syst Rev*. 2014;3:CD009454.
25. Paek SH, Audu PB, Sperling MR, Cho J, Andrews DW. Reevaluation of surgery for the treatment of brain metastases: review of 208 patients with single or multiple brain metastases treated at one institution with modern neurosurgical techniques. *Neurosurgery*. 2005;56:1021-1034; discussion 1021-1034.
26. Kalkanis SN, Kondziolka D, Gaspar LE, et al. The role of surgical resection in the management of newly diagnosed brain metastases: a systematic review and evidence-based clinical practice guideline. *J Neurooncol*. 2010;96:33-43.
27. Bindal RK, Sawaya R, Leavens ME, Lee JJ. Surgical treatment of multiple brain metastases. *J Neurosurg*. 1993;79:210-216.
28. Bindal RK, Sawaya R, Leavens ME, Hess KR, Taylor SH. Reoperation for recurrent metastatic brain tumors. *J Neurosurg*. 1995;83:600-604.
29. Mahajan A, Ahmed S, McAleer MF, et al. Post-operative stereotactic radiosurgery versus observation for completely resected brain metastases: a single-centre, randomised, controlled, phase 3 trial. *Lancet Oncol*. 2017;18:1040-1048.
30. Brown PD, Ballman KV, Cerhan JH, et al. Postoperative stereotactic radiosurgery compared with whole brain radiotherapy for resected metastatic brain disease (NCCTG N107C/CEC.3): a multicentre, randomised, controlled, phase 3 trial. *Lancet Oncol*. 2017;18:1049-1060.
31. Gui C, Moore J, Grimm J, et al. Local recurrence patterns after postoperative stereotactic radiation surgery to resected brain metastases: a quantitative analysis to guide target delineation. *Pract Radiat Oncol*. 2018;8:388-396.
32. Prabhu RS, Miller KR, Asher AL, et al. Preoperative stereotactic radiosurgery before planned resection of brain metastases: updated analysis of efficacy and toxicity of a novel treatment paradigm. *J Neurosurg*. 2019;131:1347-1682.
33. Langer CJ, Mehta MP. Current management of brain metastases, with a focus on systemic options. *J Clin Oncol*. 2005;23:6207-6219.
34. Davies MA, Saiag P, Robert C, et al. Dabrafenib plus trametinib in patients with BRAF(V600)-mutant melanoma brain metastases (COMBI-MB): a multicentre, multicohort, open-label, phase 2 trial. *Lancet Oncol*. 2017;18:863-873.
35. Long GV, Atkinson V, Lo S, et al. Combination nivolumab and ipilimumab or nivolumab alone in melanoma brain metastases: a multicentre randomised phase 2 study. *Lancet Oncol*. 2018;19:672-681.
36. Tawbi HA, Forsyth PA, Algazi A, et al. Combined nivolumab and ipilimumab in melanoma metastatic to the brain. *N Engl J Med*. 2018;379:722-730.
37. Tawbi HAH, Forsyth PAJ, Hodi FS, et al. Efficacy and safety of the combination of nivolumab (NIVO) plus ipilimumab (IPI) in patients with symptomatic melanoma brain metastases (CheckMate 204) [abstract]. *J Clin Oncol*. 2019;37(15 suppl):9501.
38. Wrona A, Dziadziuszko R, Jassem J. Management of brain metastases in non-small cell lung cancer in the era of tyrosine kinase inhibitors. *Cancer Treat Rev*. 2018;71:59-67.
39. Sehgal K, Patell R, Rangachari D, Costa DB. Targeting ROS1 rearrangements in non-small cell lung cancer with crizotinib and other kinase inhibitors. *Transl Cancer Res*. 2018;7(suppl 7):S779-S786.
40. Demetri GD, Paz-Ares L, Farago AF, et al. LBA4. Efficacy and safety of entrectinib in patients with NTRK fusion-positive tumours: pooled analysis of STARTRK-2, STARTRK-1, and ALKA-372-001 [abstract]. *Ann Oncol*. 2018;29(suppl 9):mdy483.003.
41. Magnuson WJ, Lester-Coll NH, Wu AJ, et al. Management of brain metastases in tyrosine kinase inhibitor-naive epidermal growth factor receptor-mutant non-small-cell lung cancer: a retrospective multiinstitutional Analysis. *J Clin Oncol*. 2017;35:1070-1077.
42. Lim SH, Lee JY, Lee MY, et al. A randomized phase III trial of stereotactic radiosurgery (SRS) versus observation for patients with asymptomatic cerebral oligo-metastases in non-small-cell lung cancer. *Ann Oncol*. 2015;26:762-768.
43. Gandhi L, Rodriguez-Abreu D, Gadgeel S, et al. Pembrolizumab plus chemotherapy in metastatic non-small-cell lung Cancer. *N Engl J Med*. 2018;378:2078-2092.
44. Paz-Ares L, Luft A, Vicente D, et al. Pembrolizumab plus chemotherapy for squamous non-small-cell lung cancer. *N Engl J Med*. 2018;379:2040-2051.

10970142, 2020, 7, Downloaded from https://acsjournals.onlinelibrary.wiley.com/doi/10.1002/cncr.32714, Wiley Online Library on [03/02/2026]. See the Terms and Conditions (https://onlinelibrary.wiley.com/terms-and-conditions) on Wiley Online Library for rules of use; OA articles are governed by the applicable Creative Commons License

45. Goldberg SB, Gettinger SN, Mahajan A, et al. Pembrolizumab for patients with melanoma or non-small-cell lung cancer and untreated brain metastases: early analysis of a non-randomised, open-label, phase 2 trial. *Lancet Oncol*. 2016;17:976-983.
46. Fecci PE, Champion CD, Hoj J, et al. The evolving modern management of brain metastasis. *Clin Cancer Res*. 2019;25:6570-6580.
47. Saura C, Oliveira M, Feng YH, et al. Neratinib + capecitabine versus lapatinib + capecitabine in patients with HER2+ metastatic breast cancer previously treated with ≥2 HER2-directed regimens: findings from the multinational, randomized, phase III NALA trial [abstract]. *J Clin Oncol*. 2019;37(15 suppl):1002.
48. Murthy R, Borges VF, Conlin A, et al. Tucatinib with capecitabine and trastuzumab in advanced HER2-positive metastatic breast cancer with and without brain metastases: a non-randomised, open-label, phase 1b study. *Lancet Oncol*. 2018;19:880-888.
49. Cortes J, Rugo HS, Awada A, et al. Prolonged survival in patients with breast cancer and a history of brain metastases: results of a preplanned subgroup analysis from the randomized phase III BEACON trial. *Breast Cancer Res Treat*. 2017;165:329-341.
50. Schmid P, Adams S, Rugo HS, et al. IMpassion130: updated overall survival (OS) from a global, randomized, double-blind, placebo-controlled, phase III study of atezolizumab (atezo) + nab-paclitaxel (nP) in previously untreated locally advanced or metastatic triple-negative breast cancer (mTNBC) [abstract]. *J Clin Oncol*. 2019;37 (15 suppl):1003.
51. Flippot R, Dalban C, Laguerre B, et al. Safety and efficacy of nivolumab in brain metastases from renal cell carcinoma: results of the GETUG-AFU 26 NIVOREN multicenter phase II study. *J Clin Oncol*. 2019;37:2008-2016.
52. Karivedu V, Jandarov R, Wise-Draper TM. Brain metastases treated with immune checkpoint inhibitors: a single center experience [abstract]. *J Clin Oncol*. 2018;36(15 suppl):e14012.
53. Minniti G, Laack NN, Halasz LM, Chan MD, Soltys SG, Kirkpatrick JP. Can we omit radiation therapy in the treatment of brain metastases from melanoma? *Int J Radiat Oncol Biol Phys*. 2019;104:473-477.
54. Chen L, Douglass J, Kleinberg L, et al. Concurrent immune checkpoint inhibitors and stereotactic radiosurgery for brain metastases in non-small cell lung cancer, melanoma, and renal cell carcinoma. *Int J Radiat Oncol Biol Phys*. 2018;100:916-925.
55. Lehrer EJ, Peterson J, Brown PD, et al. Treatment of brain metastases with stereotactic radiosurgery and immune checkpoint inhibitors: an international meta-analysis of individual patient data. *Radiother Oncol*. 2019;130:104-112.
56. Olson AC, Thomas S, Qin R, et al. Outcomes and toxicity of stereotactic radiosurgery for melanoma brain metastases in patients receiving ipilimumab. *Melanoma Manag*. 2016;3:177-186.
57. Schapira E, Hubbeling H, Yeap BY, et al. Improved overall survival and locoregional disease control with concurrent PD-1 pathway inhibitors and stereotactic radiosurgery for lung cancer patients with brain metastases. *Int J Radiat Oncol Biol Phys*. 2018;101: 624-629.
58. Aoyama H, Shirato H, Tago M, et al. Stereotactic radiosurgery plus whole-brain radiation therapy vs stereotactic radiosurgery alone for treatment of brain metastases: a randomized controlled trial. *JAMA*. 2006;295:2483-2491.
59. Brown PD, Jaeckle K, Ballman KV, et al. Effect of radiosurgery alone vs radiosurgery with whole brain radiation therapy on cognitive function in patients with 1 to 3 brain metastases: a randomized clinical trial. *JAMA*. 2016;316:401-409.
60. Chang EL, Wefel JS, Hess KR, et al. Neurocognition in patients with brain metastases treated with radiosurgery or radiosurgery plus whole-brain irradiation: a randomised controlled trial. *Lancet Oncol*. 2009;10:1037-1044.
61. Kocher M, Soffietti R, Abacioglu U, et al. Adjuvant whole-brain radiotherapy versus observation after radiosurgery or surgical resection of one to three cerebral metastases: results of the EORTC 22952-26001 study. *J Clin Oncol*. 2011;29:134-141.
62. Patchell RA, Tibbs PA, Regine WF, et al. Postoperative radiotherapy in the treatment of single metastases to the brain: a randomized trial. *JAMA*. 1998;280:1485-1489.
63. Barbour AB, Jacobs CD, Williamson H, et al. Radiation therapy practice patterns for brain metastases in the United States in the stereotactic radiosurgery era [published online July 28, 2019]. *Adv Radiat Oncol*. doi:10.1016/j.adro.2019.07.012
64. Trifiletti DM, Ballman KV, Brown PD, et al. Optimizing whole brain radiotherapy dose and fractionation: results from a prospective phase 3 trial (NCCTG N107C [Alliance]/CEC.3) [published online October 22, 2019]. *Int J Radiat Oncol Biol Phys*. doi:10.1016/;joj.ijrobp.2019.10.024
65. Verduin M, Zindler JD, Martinussen HM, et al. Use of systemic therapy concurrent with cranial radiotherapy for cerebral metastases of solid tumors. *Oncologist*. 2017;22:222-235.
66. Shaw E, Scott C, Souhami L, et al. Single dose radiosurgical treatment of recurrent previously irradiated primary brain tumors and brain metastases: final report of RTOG protocol 90-05. *Int J Radiat Oncol Biol Phys*. 2000;47:291-298.
67. Andrews DW, Scott CB, Sperduto PW, et al. Whole brain radiation therapy with or without stereotactic radiosurgery boost for patients with one to three brain metastases: phase III results of the RTOG 9508 randomised trial. *Lancet*. 2004;363:1665-1672.
68. Kondziolka D, Patel A, Lunsford LD, Kassam A, Flickinger JC. Stereotactic radiosurgery plus whole brain radiotherapy versus radiotherapy alone for patients with multiple brain metastases. *Int J Radiat Oncol Biol Phys*. 1999;45:427-434.
69. Yamamoto M, Serizawa T, Shuto T, et al. Stereotactic radiosurgery for patients with multiple brain metastases (JLGK0901): a multi-institutional prospective observational study. *Lancet Oncol*. 2014; 15:387-395.
70. Horton J, Baxter DH, Olson KB. The management of metastases to the brain by irradiation and corticosteroids. *Am J Roentgenol Radium Ther Nucl Med*. 1971;111:334-336.
71. Mulvenna P, Nankivell M, Barton R, et al. Dexamethasone and supportive care with or without whole brain radiotherapy in treating patients with non-small cell lung cancer with brain metastases unsuitable for resection or stereotactic radiotherapy (QUARTZ): results from a phase 3, non-inferiority, randomised trial. *Lancet*. 2016;388: 2004-2014.
72. Baliga S, Garg MK, Fox J, et al. Fractionated stereotactic radiation therapy for brain metastases: a systematic review with tumour control probability modelling. *Br J Radiol*. 2017;90:20160666.
73. Marchan EM, Peterson J, Sio TT, et al. Postoperative cavity stereotactic radiosurgery for brain metastases. *Front Oncol*. 2018;8:342.
74. Limon D, McSherry F, Herndon J, et al. Single fraction stereotactic radiosurgery for multiple brain metastases. *Adv Radiat Oncol*. 2017;2:555-563.
75. Carpentier A, McNichols RJ, Stafford RJ, et al. Laser thermal therapy: real-time MRI-guided and computer-controlled procedures for metastatic brain tumors. *Lasers Surg Med*. 2011;43:943-950.
76. Carpentier A, McNichols RJ, Stafford RJ, et al. Real-time magnetic resonance-guided laser thermal therapy for focal metastatic brain tumors. *Neurosurgery*. 2008;63(1 suppl):ONS21-ONS28; discussion ONS28-ONS29.
77. Chaunzwa TL, Deng D, Leuthardt EC, et al. Laser thermal ablation for metastases failing radiosurgery: a multicentered retrospective study. *Neurosurgery*. 2018;82:56-63.
78. Iyer A, Halpern CH, Grant GA, Deb S, Li GH. Magnetic resonance-guided laser-induced thermal therapy for recurrent brain metastases in the motor strip after stereotactic radiosurgery. *Cureus*. 2016;8:e919.
79. Sloan AE, Ahluwalia MS, Valerio-Pascua J, et al. Results of the NeuroBlate System first-in-humans phase I clinical trial for recurrent glioblastoma: clinical article. *J Neurosurg*. 2013;118:1202-1219.
80. Sugiyama K, Sakai T, Fujishima I, Ryu H, Uemura K, Yokoyama T. Stereotactic interstitial laser-hyperthermia using Nd-YAG laser. *Stereotact Funct Neurosurg*. 1990;54-55:501-505.
81. Rennert RC, Khan U, Tatter SB, et al. Patterns of clinical use of stereotactic laser ablation: analysis of a multicenter prospective registry. *World Neurosurg*. 2018;116:e566-e570.
82. Rao MS, Hargreaves EL, Khan AJ, Haffty BG, Danish SF. Magnetic resonance-guided laser ablation improves local control for postradiosurgery recurrence and/or radiation necrosis. *Neurosurgery*. 2014; 74:658-667; discussion 667.

10970142, 2020, 7, Downloaded from https://acsjournals.onlinelibrary.wiley.com/doi/10.1002/cncr.32714, Wiley Online Library on [03/02/2026]. See the Terms and Conditions (https://onlinelibrary.wiley.com/terms-and-conditions) on Wiley Online Library for rules of use; OA articles are governed by the applicable Creative Commons License

83. Torres-Reveron J, Tomasiewicz HC, Shetty A, Amankulor NM, Chiang VL. Stereotactic laser induced thermotherapy (LITT): a novel treatment for brain lesions regrowing after radiosurgery. *J Neurooncol*. 2013;113:495-503.
84. Rahmathulla G, Recinos PF, Valerio JE, Chao S, Barnett GH. Laser interstitial thermal therapy for focal cerebral radiation necrosis: a case report and literature review. *Stereotact Funct Neurosurg*. 2012; 90:192-200.
85. Fabiano AJ, Alberico RA. Laser-interstitial thermal therapy for refractory cerebral edema from post-radiosurgery metastasis. *World Neurosurg*. 2014;81:652.e1-e4.
86. Hong CS, Deng D, Vera A, Chiang VL. Laser-interstitial thermal therapy compared to craniotomy for treatment of radiation necrosis or recurrent tumor in brain metastases failing radiosurgery. *J Neurooncol*. 2019;142:309-317.
87. Ahluwalia M, Barnett GH, Deng D, et al. Laser ablation after stereotactic radiosurgery: a multicenter prospective study in patients with metastatic brain tumors and radiation necrosis. *J Neurosurg*. 2018;130:804-811.
88. Ali MA, Carroll KT, Rennert RC, et al. Stereotactic laser ablation as treatment for brain metastases that recur after stereotactic radiosurgery: a multiinstitutional experience. *Neurosurg Focus*. 2016;41:E11.
89. Natarajan BD, Rushing CN, Cummings MA, et al. Predicting intracranial progression following stereotactic radiosurgery for brain metastases: implications for post SRS imaging. *J Radiosurg SBRT*. 2019;6:79-187.
90. Lin NU, Lee EQ, Aoyama H, et al. Challenges relating to solid tumour brain metastases in clinical trials, part 1: patient population, response, and progression. A report from the RANO group. *Lancet Oncol*. 2013;14:e396-e406.
91. Lin NU, Wefel JS, Lee EQ, et al. Challenges relating to solid tumour brain metastases in clinical trials, part 2: neurocognitive, neurological, and quality-of-life outcomes. A report from the RANO group. *Lancet Oncol*. 2013;14:e407-e416.
92. Lin NU, Lee EQ, Aoyama H, et al. Response assessment criteria for brain metastases: proposal from the RANO group. *Lancet Oncol*. 2015;16:e270-e278.
93. Day J, Zienius K, Gehring K, et al. Interventions for preventing and ameliorating cognitive deficits in adults treated with cranial irradiation. *Cochrane Database Syst Rev*. 2014;12:CD011335.
94. Rapp SR, Case LD, Peiffer A, et al. Donepezil for irradiated brain tumor survivors: a phase III randomized placebo-controlled clinical trial. *J Clin Oncol*. 2015;33:1653-1659.
95. Gondi V, Pugh SL, Tome WA, et al. Preservation of memory with conformal avoidance of the hippocampal neural stem-cell compartment during whole-brain radiotherapy for brain metastases (RTOG 0933): a phase II multi-institutional trial. *J Clin Oncol*. 2014;32:3810-3816.
96. Gondi V, Deshmukh S, Brown PD, et al. NRG Oncology CC001: a phase III trial of hippocampal avoidance (HA) in addition to whole-brain radiotherapy (WBRT) plus memantine to preserve neurocognitive function (NCF) in patients with brain metastases (BM) [abstract]. *J Clin Oncol*. 2019;37(15 suppl):2009.
97. Gondi V, Pugh S, Brown PD, et al. Significant preservation of neurocognitive function (NCF) and patient-reported symptoms with hippocampal avoidance (HA) during whole-brain radiotherapy (WBRT) for brain metastases: final results of NRG Oncology CC001. *Int J Radiat Oncol Biol Phys*. 2018;105(suppl):S12-S13.
98. Vellayappan B, Tan CL, Yong C, et al. Diagnosis and management of radiation necrosis in patients with brain metastases. *Front Oncol*. 2018;8:395.
99. Narloch JL, Farber SH, Sammons S, et al. Biopsy of enlarging lesions after stereotactic radiosurgery for brain metastases frequently reveals radiation necrosis. *Neuro Oncol*. 2017;19:1391-1397.
100. Verma N, Cowperthwaite MC, Burnett MG, Markey MK. Differentiating tumor recurrence from treatment necrosis: a review of neuro-oncologic imaging strategies. *Neuro Oncol*. 2013;15: 515-534.
101. Chuang MT, Liu YS, Tsai YS, Chen YC, Wang CK. Differentiating radiation-induced necrosis from recurrent brain tumor using MR perfusion and spectroscopy: a meta-analysis. *PLoS One*. 2016;11:e0141438.
102. Asao C, Korogi Y, Kitajima M, et al. Diffusion-weighted imaging of radiation-induced brain injury for differentiation from tumor recurrence. *AJNR Am J Neuroradiol*. 2005;26:1455-1460.
103. Jones KM, Michel KA, Bankson JA, Fuller CD, Klopp AH, Venkatesan AM. Emerging magnetic resonance imaging technologies for radiation therapy planning and response assessment. *Int J Radiat Oncol Biol Phys*. 2018;101:1046-1056.
104. Xu Y, Rong X, Hu W, et al. Bevacizumab monotherapy reduces radiation-induced brain necrosis in nasopharyngeal carcinoma patients: a randomized controlled trial. *Int J Radiat Oncol Biol Phys*. 2018; 101:1087-1095.
105. McPherson CM, Warnick RE. Results of contemporary surgical management of radiation necrosis using frameless stereotaxis and intraoperative magnetic resonance imaging. *J Neurooncol*. 2004;68:41-47.
106. Smith CJ, Myers CS, Chapple KM, Smith KA. Long-Term follow-up of 25 cases of biopsy-proven radiation necrosis or post-radiation treatment effect treated with magnetic resonance-guided laser interstitial thermal therapy. *Neurosurgery*. 2016;79(suppl 1):S59-S72.
107. Hardesty DA, Nakaji P. The current and future treatment of brain metastases. *Front Surg*. 2016;3:30.
108. Ding L, Ellis MJ, Li S, et al. Genome remodelling in a basal-like breast cancer metastasis and xenograft. *Nature*. 2010;464:999-1005.
109. Brastianos PK, Carter SL, Santagata S, et al. Genomic characterization of brain metastases reveals branched evolution and potential therapeutic targets. *Cancer Discov*. 2015;5:1164-1177.
110. Kotecha R, Gondi V, Ahluwalia MS, Brastianos PK, Mehta MP. Recent advances in managing brain metastasis. *F1000Res*. 2018;7:pii: F1000 Faculty Rev-1772.

10970142, 2020, 7, Downloaded from https://acsjournals.onlinelibrary.wiley.com/doi/10.1002/cncr.32714, Wiley Online Library on [03/02/2026]. See the Terms and Conditions (https://onlinelibrary.wiley.com/terms-and-conditions) on Wiley Online Library for rules of use; OA articles are governed by the applicable Creative Commons License